

## The Forehead Flap is a Valuable Loco-Regional Reconstructive Option: In Selected Head and Neck Carcinoma Patients

KHALED EL-GAZZAR, M.D.\* and ANAS ASKOURA, M.D.\*\*

*The Departments of Plastic & Reconstructive Surgery\* and Otorhinolaryngology\*\*, Faculty of Medicine, Ain Shams University, Cairo*

### ABSTRACT

**Introduction:** The forehead flap is a valuable reconstructive option for head and neck defects. Reconstructive surgeon resorts to loco-regional flaps when palliative excision is planned or during management of patients with multiple comorbidities making free flap based reconstruction as an unwise decision.

**Patients and Methods:** Thirteen patients were included in this study that was conducted between March 2013 and January 2016. The forehead flap was used for reconstruction of different post-tumour excision head and neck defects.

**Results:** The forehead flap survival rate was 100% in our study, with successful reconstruction of different calvarial, orbital, maxillary, buccal, and mandibular defects. (Five cases as covering and 7 cases as covering and lining).

**Conclusion:** In selected cases as in advanced carcinomas and/or in patients with general comorbidities; the forehead flap is a more valuable reconstructive modality than free flaps.

**Key Words:** Forehead flap – Head & neck carcinoma.

### INTRODUCTION

The forehead flap was used as early as the 700 B.C. It was described in an ancient Indian medical document named “Sushruta Samhita” for nasal reconstruction [1]. The basic principles for this flap were refined and modified by many authors as Carpue, Kazanjian, Millard, Burget, and Menick. These refinements aimed to decrease the donor site morbidity and the vascular compromise seen in some patients [2].

The blood supply of the forehead flap comes through three main vascular sources that are represented bilaterally. The superficial temporal, supraorbital, and the supratrochlear vessels [3,4,5]. In the paramedian territory the supratrochlear vessels share with supraorbital and dorsal nasal vessels in the supraorbital vascular plexus [4].

The forehead flap is widely used for nasal reconstruction in recent practice. Still surgeons may resort to the forehead flap for reconstruction

of other cervico-facial defects. The forehead flap provides an excellent loco-regional reconstructive option in many situations [6].

Although, the free flap is the work horse flap for reconstruction of head and neck sizable complex defects, [7,8,9] in selected patients the choice of free flap is not feasible. This can be attributed to several general and local factors that make some patients unfit for free flap reconstruction. The general condition of the patient is affected the advanced tumour stages with low 5 years survival rates, or in the presence of general comorbidities as Ischemic Heart Disease (IHD), systemic vascular disease e.g. Systemic Lupus Erythematosus (SLE), Chronic renal disease (CRD), history of cerebral strokes, etc. [10,11].

The defect local condition may be also an obstacle for free flap reconstruction. As in cases of recipient vessels depletion at the defect site; due to failed previous microvascular reconstruction session, or in cases with radical neck dissections or irradiation. Also, in some patients with locally advanced carcinomas; especially when palliative excision is planned [10].

The reconstructive surgeon resorts to loco-regional flaps whenever the free flap is not feasible. The loco-regional flaps are easily executed with short operative timing. Among the loco-regional flaps, the forehead flap offers a valuable reconstruction option in the era of microsurgery; it has many advantages such as; the wide skin territory with robust vascularity and excellent match as regards the colour, thickness, and absence of hair. Also, the pliability of the forehead skin enables for three-dimensional (3D) reconstruction of head and neck defects. In this study, we highlight the reconstruction value of the forehead flap during management of patients with multiple co-morbidities or advanced carcinomas.

## PATIENTS AND METHODS

This study was conducted during the period between March 2013 and January 2016. This study included 13 patients with head and neck carcinomas; suffering from multiple comorbidities or in advanced stages (Tables 1,2). The patients were 12 males and 1 female. Their ages ranged between 57 and 83 (mean age was 73.3) (Table 1). A Multidisciplinary team (MDT) meetings were held involving the oncology, neurosurgery, Ear, Nose and throat, ophthalmology and the plastic reconstructive surgery teams; to discuss the plan of management and the expected outcome for all patients.

The general condition of all patients were improved pre-operatively. This was done in collaboration with the nutrition out-patient clinic at the oncology department. Feeding nasogastric tubes were inserted into 4 patients (n=4) with swallowing difficulties; two cases of mandibular carcinomas and one case of buccal carcinoma. The feeding gastrostomy was indicated in one patient (n=1) with advanced mandibular carcinoma. Central venous catheterisation was indicated in all patients (n=13) for blood and plasma transfusion; patient central venous pressure monitoring; or for total parental nutrition (TPN) if needed in the post-operative period.

Table (1): Age, sex and the general comorbidities among patients included in this study.

No.	Age	Sex	General Comorbidities
1	78	M	IHD
2	81	M	CRD/on dialysis
3	69	M	HBV +ve
4	62	M	Cerebral stroke, history of local radiation.
5	57	F	SLE, BMI=46
6	68	M	DM, hypertension, IHD.
7	77	M	HCV +ve
8	73	M	Chronic haemolytic anaemia.
9	83	M	Hypertension.
10	76	M	IHD, DM
11	79	M	Hypertension, cerebral stroke.
12	71	M	–
13	80	M	IHD, DM

### Abbreviations:

IHD : Ischemic heart disease.

CRD : Chronic renal disease.

HBV : Hepatitis B virus.

SLE : Systemic Lupus Erythematosus.

BMI: Body mass index.

D.M.: Diabetes mellitus.

HCV: Hepatitis C virus.

In 4 patients (n=4, 30% of included patients) with advanced SCC affecting the cheek buccal mucosa (N=2) and the mandible (n=2), palliative excision was decided for tumour downgrading; giving the patients better quality of life and increasing the tumour susceptibility for the palliative radio-chemotherapy protocols later on (Table 2).

### Surgical procedure:

In conjunction with neurosurgery team; the scalp SCC or the meningioma was excised with the related calvarium if included with the safety margins. Before reconstruction with the forehead flap; the neurosurgery team insured dural reconstruction if indicated. Ophthalmology team underwent right orbital exenteration in conjunction with the neurosurgery team in a single case; where the patient suffered from orbital recurrent BCC. The ear, nose, and throat team in conjunction with the plastic team underwent modified radical neck dissection for management of cases associated with metastatic neck lymphadenopathies (Table 2).

The laterally based forehead flap elevation started with the upper incision at the hair line for easier identification of planes. The flap dissection proceeded from the distal end including the contralateral superficial temporal vessels running in a plane superficial to the forehead pericarnium. The distal end of the flap is extended in a V-shaped fashion to facilitate direct closure of the donor area at the pre-auricular region. Then the whole vertical height of the forehead till the upper margins of the eye brows; was included in the flap to harvest the total aesthetic unit. The width of the flap is narrowed in proximity to the pedicle; this was done to include only the superficial temporal vessels in the pedicle.

In patients with past history of radiation, the pedicle base was extended to the post auricular area to include the post auricular vascular system; which can enhance the flap vascularity. In one patient with fungating SCC of the lower lip and mandible, a bipediced forehead flap was used to reconstruct the resultant defect after the resection.

The flap was transposed to the defect site without tension. In patients with mid face and mandibular defects; the forehead flap was used to reconstruct the surface defect and folded upon itself with de-epithelialized bridge to reconstruct the oral lining as well. In maxillary defects temporary thermoplastic wax (Fig. 1) was used to obliterate the resultant cavity. As a preparatory stage for palatal obturator insertion; this wax was left only for 10 days. In mandibular defects, the skeletal

reconstruction was achieved by reconstruction plate.

The donor site of the flap was closed with thick split thickness skin graft; preferably one sheet to provide better aesthetic outcome.

The excised tissues were send for histopathological examination, to confirm the preoperative diagnosis and for proper oncological grading. Accordingly, the post-operative radio-chemotherapy protocol was decided.

In patients with maxillary, buccal, and mandibular defects; post-operative oral feeding was postponed till complete healing of the intra-oral suture line. Nutrition was supplied through naso-gastric tube in 6 patients and feeding gastrostomy was used for 1 patient.

#### Follow-up:

The mean follow up period was  $\approx$  5.5 months. The patients were transferred to the oncology department 4 to 10 weeks post-operative (mean  $\approx$  7 weeks).

Table (2): Pathology, resultant defect after resection, reconstructive procedure done for every patient using the laterally based forehead flap.

No.	Pathology	Defect site	Procedure
1	SCC of the scalp (occipital region)	Full thickness calvarial defect (9cm)	Coverage+calvarial reconstruction with titanium mesh
2	SCC of the scalp (parietal region)	Full thickness calvarial defect (10X8cm)	Coverage only
3	SCC of the scalp (Temporo-parietal region)	Scalp defect (11cm diameter)	Coverage
4	Recurrent meningioma (grade II)	Full thickness calvarial defect including the dura (13cm diameter)	Coverage+titanium mesh+Dural graft
5	Recurrent BCC of the right orbital region	Orbito-frontal defect with exposed dura	Resection included right orbital exenteration. Coverage+titanium mesh.
6	SCC of the left maxilla	Post maxillectomy full thickness mid face defect	Coverage+lining+thermoplastic wax.
7	SCC of the left maxilla	Post maxillectomy full thickness defect of the left cheek, nasal side and anterior palate	Coverage+lining+thermoplastic wax.
8	SCC of the right maxilla + ipsilateral metastatic lymphadenopathy.	Post maxillectomy full thickness mid face defect	Coverage+lining+thermoplastic wax+ipsilateral modified neck dissection
9	SCC of right buccal mucosa, mandibular ramus encroaching the carotid sheath + ipsilateral metastatic neck lymphadenopathy.	Full thickness right cheek defect	Coverage+lining+ipsilateral modified neck dissection (palliative excision)
10	SCC of the right buccal vestibular mucosa + bilateral metastatic neck lymphadenopathy.	Full thickness right cheek defect	Coverage+lining+bilateral modified neck dissection. (palliative excision)
11	Right sided mandibular SCC + ipsilateral metastatic neck lymphadenopathy.	Full thickness defect of lower 1/3 face	Coverage+lining+reconstruction plate+ipsilateral modified neck dissection
12	SCC of the lower lip + central mandible and floor of mouth involvement + bilateral metastatic neck lymphadenopathy.	Full thickness mandibular defect.	Bipedicled forehead flap for coverage and lining+reconstruction plate+bilateral modified neck dissection. (Palliative excision)
13	Recurrent right sided mandibular SCC + previous reconstruction session (PM myocutaneous flap)	Full thickness defect of lower 1/3 face	Coverage+lining (palliative excision)

#### Abbreviations:

SCC: Squamous cell carcinoma. BCC: Basal cell carcinoma. PM: Pectoralis Major muscle.

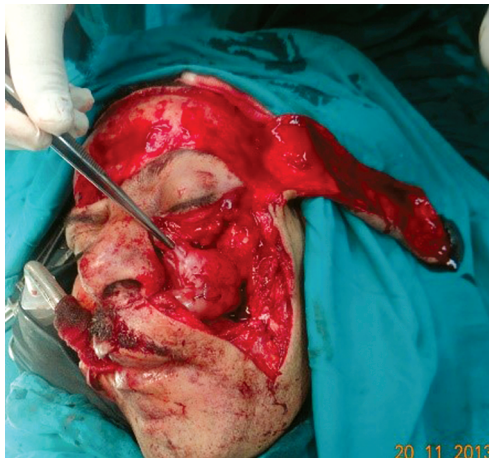

Fig. (1): Intra-operative packing of the maxillary defects with temporary thermoplastic wax.

**RESULTS**

All forehead flaps survived with no single case of total loss (survival rate=100%). In patients with calvarial and orbital defects (Figs. 2-4), the forehead flaps successfully covered the defects with no exposure of the underlying Titanium meshes. The sutures were removed 2 to 3 weeks post-operative. The patient with the orbital defect suffered from CSF rhinorrhea, that ceased spontaneously one-week post-operative.

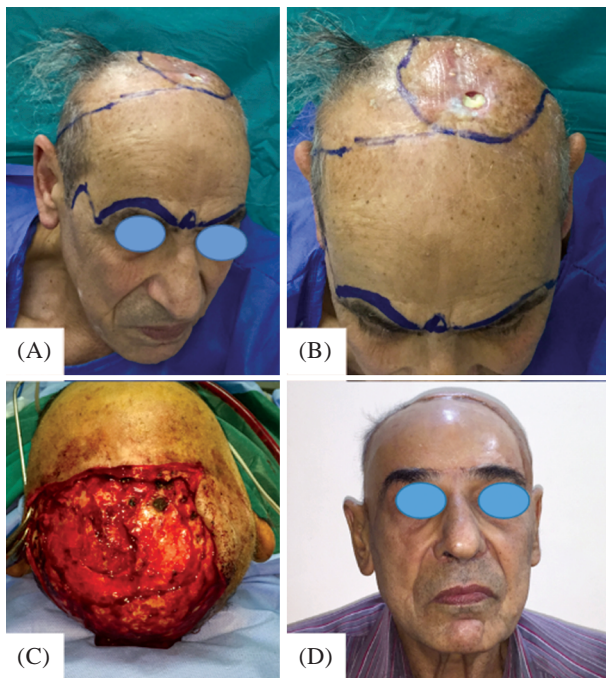


Fig. (2): A 78 years old male patient presented with chronic calvarial ulcer, histopathological examination revealed squamous cell carcinoma (SCC). A and B: the pre-operative plan and forehead flap marking. C: Intra-operative photo showing the extend of the ulcer excision. D: One-year post-operative result.

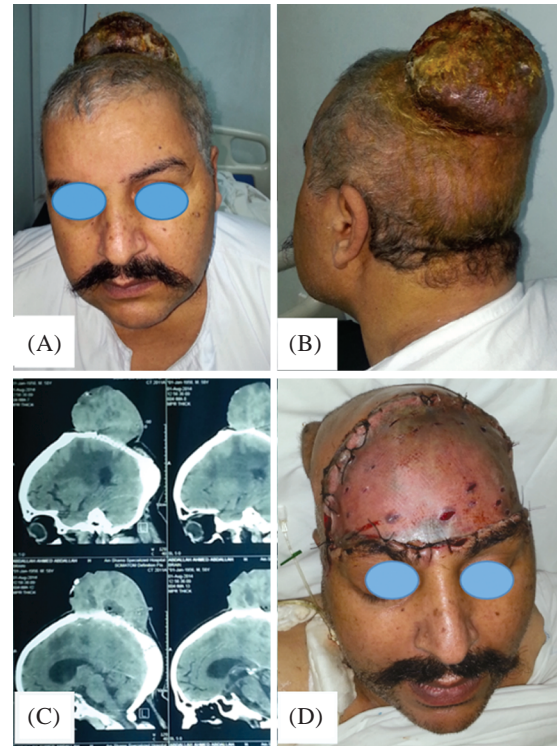

Fig. (3): A and B: Five years after excision of meningeoma and radiation protocol: A 62 years old male patient presented with scalp swelling; C: MRI sagittal cuts showing intra-cranial meningeoma with extra-cranial extension in the presence of titanium mesh. D: One-week post-operative result after resection of the meningeoma and reconstruction with forehead flap.

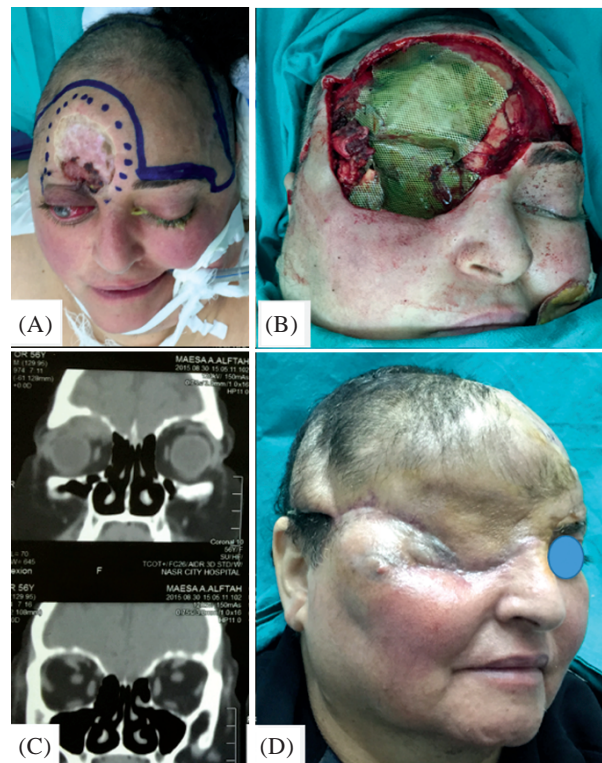


Fig. (4): A: A 57 years old female patient with recurrent Basal cell carcinoma (BCC) involving the right aspect of the forehead with ocular muscles infiltration. B: Titanium mesh application for skeletal reconstruction after orbital exenteration and resection the orbital roof, medial wall, and adjacent bones. C: CT coronal cuts showing BCC intra-orbital extension. D: Seven months post-operative result.

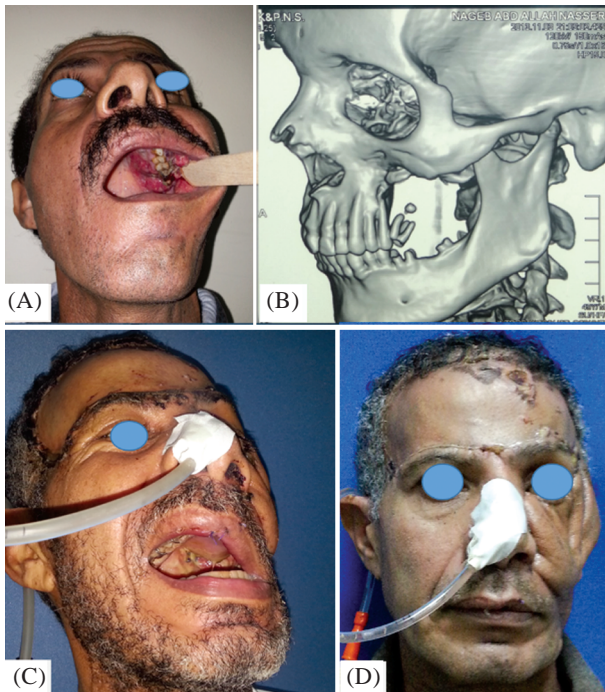


Fig. (5): A: A 68 years old male patient with SCC of left maxilla. B: CT 3D showing malignant erosion of the left maxillary bone. C and D: Three months post-operative result with complete healing of the intra-oral lining.

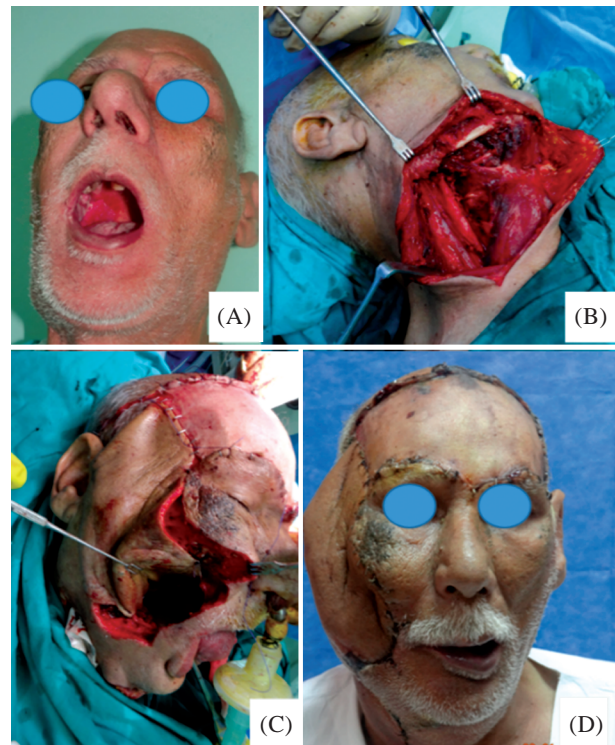

Fig. (6): A: A 83 years old male patient with SCC of right buccal mucosa. B: Intra-operation photos for ipsilateral modified radical neck dissection. C: Reconstruction of the right cheek full thickness defect with the forehead flap (Lining and coverage). D: One-month post-operative result.

Table (3): The incidence of morbidities and mortality.

Morbidities	Carcinoma site (No. of patients)	Incidence (%)	Fate
CSF leakage/Rhinorrhea	Orbital (n=1)	(7.69%)	Ceased spontaneously
Meningitis/encephalitis	–	(0%)	
Hardware exposure	–	(0%)	
Oral lining disruption	Maxillary (n=1), Buccal (n=1)	(15.38%)	
Partial skin graft loss at the donor site of the flap	Orbital (n=1), Maxillary (n=1)	(15.38%)	Healed conservatively
Recurrence of malignancy	(n=3): Buccal (cases 9,10) and Mandibular (case13)	(23%)	Case (9): carotid blowout 6 months post-operative Case (10): local recurrence + lung metastasis 14 weeks post-operative Case (13): local recurrence 3 months post-operative
Mortality (cause of death)	Carcinoma site (No. of patients)	Incidence (%)	
DIC	Mandibular (n=1)	(7.69%)	

Four patients had had palliative excisions (Case No. 9, 10, 12, 13). On the first day post-operative, one patient died with DIC after massive blood transfusion (Case No. 12). Three to six months

post-operative, three patient presented with local malignant recurrence (23%). No more surgical management was done as recommended by the oncology team, other palliation modalities were

continued (Table 3). The skin graft take occurred in all patients at the donor site of the forehead flap; except for two patients in whom small areas of skin graft loss were noticed. Healing with secondary intention was the result after proper wound care (Table 3).

The aesthetic outcome of the forehead flap donor area was satisfactory to all patients in our study. The dog ear at the flap pedicle usually atrophy during the following weeks; patient reassurance was advanced along this period. 1 year after fulfilment of the planned radio-therapy protocol; dog ear excision and refashioning were done in 1 patient to get rid of the dog ear and to manage lower eye lid ectropion simultaneously. In all patients, loss of forehead animation with variable grades of brow ptosis was recorded post-operatively.

### DISCUSSION

Although, the free flaps are the work horse flaps used for head and neck reconstruction; the forehead flap is still a valuable reconstruction option in selected patients. Using the microvascular techniques pre-requisite the presence of expert surgeon, special equipment, close flap monitoring for possibility of re-operation in case of flap vascular impairment.

Some patients with head and neck tumors are not fit for free flap reconstruction; as patients with bad general condition due to the cancer itself, or due to the presence of general co-morbidities making prolonged anesthesia very risky. In advanced carcinomas or during palliative excisions; the reconstructive surgeon should consider more simple procedures. Furthermore, local factors as absence of reliable donor vessels at the recipient site can make free flap reconstruction unfeasible.

Usually, tumor excision in the head and neck region results in complex three dimensional defects. The forehead flap provides good quality wide skin area that can adequately provide covering and lining for oral and maxillary defects. This skin is characterized with constant robust vascularity. In addition, the frontalis muscle is included in the flap that increases the durability against the post-operative radiotherapy. Even the distal part of the flap is reliable; this results in successful intra-oral lining with less incidence of fistula formation [12,13].

The forehead flap reaches different head and neck territories. It can provide coverage of the cranium till the area below the external occipital

protuberance. The forehead flap can be used in reconstruction of the upper, middle, and lower facial subunits; as well as the related intra-oral lining. Moreover, the hypopharynx reconstruction with the forehead flap showed more successful functional outcome if compared with the radial forearm free flap [14].

Unlike other local facial flaps, the forehead flap can reconstruct large facial defects with acceptable donor site morbidities. It provides single stage reconstruction; that make the forehead flap more favorable than other distant flaps as medial arm flap. The delto-pectoral flap is a regional fasciocutaneous flap that can be used for facial reconstruction. Whereas, it is an easy flap to be executed; its limitations if compared with the forehead flap are deficient reach, unreliable distal part, and may be a two-staged procedure if delay or division are needed [15].

Supraclavicular flap is another reconstruction modality that offers wide area of matching skin for facial reconstruction. Once again, its limitations if compared with the forehead flap are deficient reach and questionable vascularity in cases associated with radical neck dissection nearby the supraclavicular vessels [16,17].

The latissimus dorsi and pectoralis major musculocutaneous flaps [18] are reliable regional flaps for head and neck reconstruction. They offer highly vascular tissues for coverage that can withstand post-operative radiation. Their disadvantages include the resultant bulky tunnels, less ability to reconstruct lining due to less pliable skin, and they can't reach the orbito-cranial area [19].

The donor site morbidity is one of the main concerns about the forehead flap. The aesthetic outcome in advanced carcinomas cases is accepted by the patients. While the functional morbidities as loss of forehead animation, brow ptosis in some cases, and the sensory alterations in the scalp area; are still annoying for young patients.

#### *Conclusion:*

The forehead flap is a valuable reconstruction option after excision of head and neck tumors. Whenever, the free flap reconstruction is unfeasible; the reconstructive surgeon can resort to the forehead flap in selected cases; as in palliative excision of advanced carcinomas or in patients with multiple co-morbidities.

#### *Disclosure:*

There is no conflict of interest.

## REFERENCES

- 1- Oo K.K. and Park S.S.: The midline forehead flap in nasal reconstruction. *Facial Plast. Surg. Clin. North Am.*, 19: 141-155, 2011.
- 2- Sachin S. Pawara and Michael M. Kim: Updates in forehead flap reconstruction of facial defects. *Curr. Opin. Otolaryngol. Head Neck Surg.*, 21: 384-388, 2013.
- 3- Kleintjes W.G.: Forehead anatomy: Arterial variations and venous link of the midline forehead flap. *J. Plast. Reconstr. Aesthet. Surg.*, 60: 593-606, 2007.
- 4- Reece E.M., Schaverien M. and Rohrich R.J.: The paramedian forehead flap: A dynamic anatomical vascular study verifying safety and clinical implications. *Plast. Reconstr. Surg.*, 121: 1956-1963, 2008.
- 5- Marur T., Tuna Y. and Demirci S.: Facial anatomy. *Clin. Dermatol.*, 32: 14-23, 2014.
- 6- Expanded Forehead Flaps for Reconstruction of Different Faciocervical Units: Selection of Flap Types Based on 143 Cases. Qianwen Wang, Weiming Song, Jiaqi Wang, et al. *Plast. Reconstr. Surg.*, 135: 1461, 2015.
- 7- Demirkan F., Chen H.C., Wei F.C., et al.: The versatile anterolateral thigh flap: a musculocutaneous flap in disguise in head and neck reconstruction. *Br. J. Plast. Surg.*, 53: 30-36, 2000.
- 8- Barbara S. Lutz and Fu-Chan Wei: Microsurgical Workhorse Flaps in Head and Neck Reconstruction. *Clin. Plastic Surg.*, 32: 421-430, 2005.
- 9- Hurvitz K.A., Kobayashi M. and Evans G.R.: Current options in head and neck reconstruction. *Plast. Reconstr. Surg.*, 118: 122eY133e, 2006.
- 10- Saint-Cyr M., Wong C., Buchel E.W., Colohan S. and Pederson W.C.: Free tissue transfers and replantation. *Plast. Reconstr. Surg.*, 130 (6): 858e-878e, 2012.
- 11- Lu Wang, Fengzhi Xu, Lei Shen, et al.: Forehead Flap for Simultaneous Reconstruction After Head and Neck Malignant Tumor Resection. *Annals of Plastic Surgery & Volume 00, Number 00, Month 2014.*
- 12- Kleintjes W.G.: Forehead anatomy: Arterial variations and venous link of the midline forehead flap. *J. Plast. Reconstr. Aesthet. Surg.*, 60: 593Y606, 2007.
- 13- Whetzel T.P. and Mathes S.J.: Arterial anatomy of the face: An analysis of vascular territories of perforating cutaneous vessels. *Plast. Reconstr. Surg.*, 89: 591Y603, 1992.
- 14- Shen L., Fan G.K., Zhu Y., et al.: Superficial temporal artery flap: A new option for posterior hypopharyngeal wall reconstruction. *Eur. Arch. Otorhinolaryngol.*, 268: 1017Y1021, 2011.
- 15- R.C.L. Chan and J.Y.W. Chan: "Deltopectoral Flap in the Era of Microsurgery," *Surgery Research and Practice*, 34 (1): 220-205, 2014.
- 16- Sandu K., Monnier P. and Pasche P.: Supraclavicular flap in head and neck reconstruction: Experience in 50 consecutive patients. *Eur. Arch. Otorhinolaryngol.*, 269: 1261Y1267, 2011.
- 17- Su T., Pirousis and Fernandes R.: Versatility of supraclavicular artery island flap in head and neck reconstruction of vessel-depleted and difficult necks. *J. Oral Maxillofac. Surg.*, 71 (3): 622-727, 2013.
- 18- Liu R., Gullane P. and Irish J.: Pectoralis major myocutaneous pedicled flap in head and neck reconstruction: retrospective review of indications and results in 244 consecutive cases at Toronto General Hospital. *J. Otolaryngol.*, 30 (1): 34-40, 2001.
- 19- Rigby M.H. and Hayden R.E.: Regional flaps: A move to simpler reconstruction options in head and neck. *Curr. Opin. Otolaryngology Head and Neck Surg.*, 22 (5): 401-406, 2014.